

*Surgical
Technique*
Guide

Bristow-Latarjet Instability Shoulder System
Open and Arthroscopic Techniques

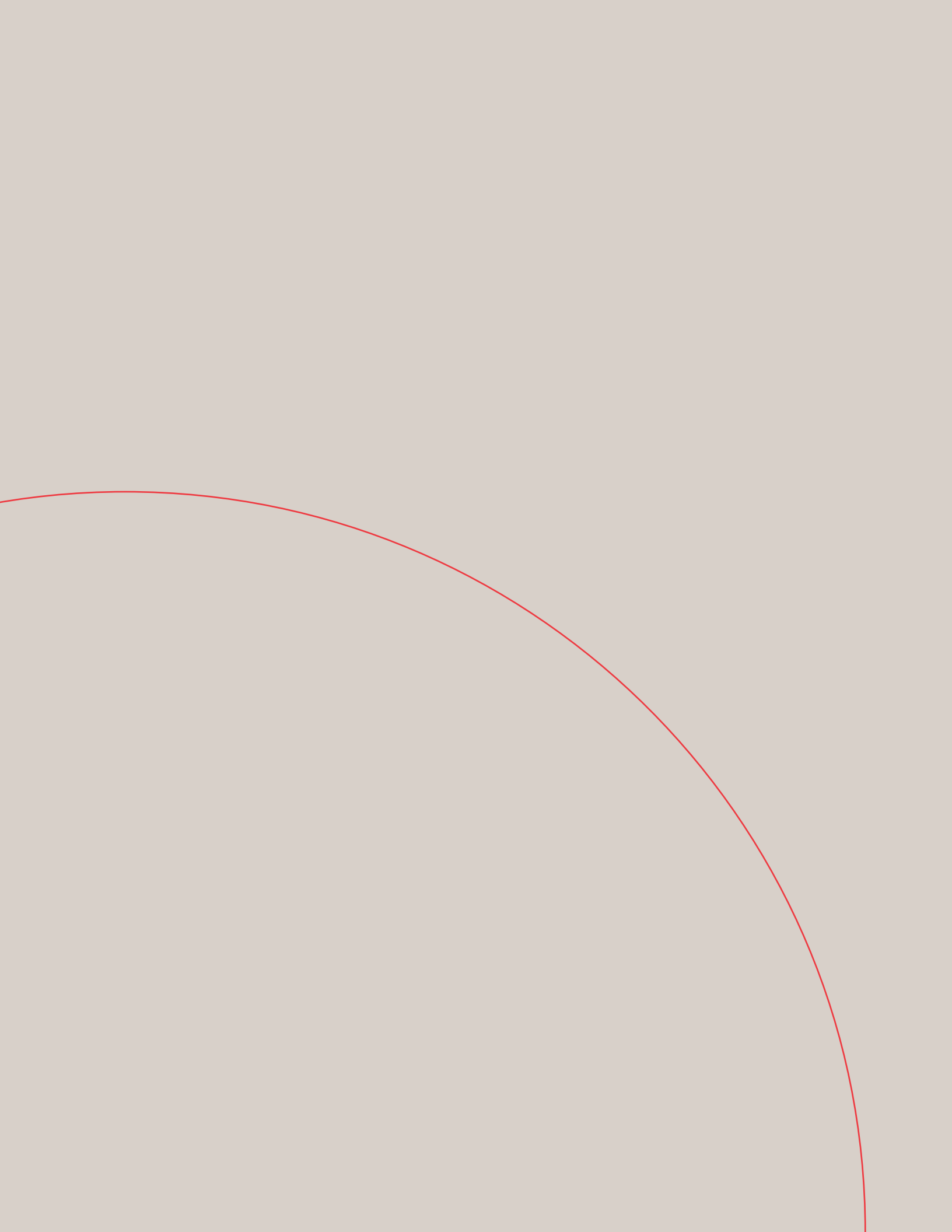




TABLE OF CONTENTS

• A LETTER FROM DR. LAFOSSE	2
• SUMMARY OF PROCEDURE	4
• THE DEPUY MITEK LATARJET INSTRUMENT PORTFOLIO	5
• PORTALS	7
• LATARJET ARTHROSCOPIC SURGICAL TECHNIQUE	8
• EVALUATION OF SHOULDER	9
• SHOULDER'S ELEMENTS ACCESS, EXPOSURE & PREPARATION	10
• LATARJET OPEN SURGICAL TECHNIQUE	21

A LETTER FROM DR. LAFOSSE

Dear Friends,

Shoulder Instability has been treated differently with time evolution. We know that soft tissue repair is not always effective for shoulder stabilization. A new arthroscopic concept of shoulder bone block stabilization has been developed on the base of the Latarjet procedure to hit the advantages of both techniques. Let me give you my beliefs on this procedure:



Why a Latarjet procedure?

In 1954, Dr. M Latarjet¹ described his technique of transferring the horizontal part of the coracoid to the anterior inferior margin of the glenoid from the 2 o'clock to the 6 o'clock position. The original procedure required detachment of the upper part of the subscapularis, but this has since been modified to place the graft through a horizontal split in the subscapularis and affix it to the glenoid with 2 screws.

Patte et al² explained the success of the open Latarjet procedure by virtue of the triple-blocking effect. We interpret the triple-block effect first by the bony reconstruction of the anterior glenoid, which serves to increase the glenoid articular arc. This prevents an otherwise engaging Hill-Sachs lesion from levering on the potentially deficient anteroinferior glenoid rim.

Secondly, the split of the subscapularis tendon provides dynamic stability in abduction and external rotation due to the tension created by its intersection with the newly positioned conjoint tendon.

The sling effect of the conjoint tendon crossing the subscapularis has a significant effect on the stability of the shoulder in external rotation after 90° of abduction as it has been proven by biomechanical studies.

Why an arthroscopic Latarjet?

The natural evolution of this procedure was to develop an all-arthroscopic technique that captures all of the advantages of the open procedure while using a minimally invasive technique.

Since December 2003, we have performed over 300 arthroscopic Latarjet procedures. The all-arthroscopic Latarjet is a reliable but difficult technique, with a steep learning curve.

Our technique has shown excellent results through midterm follow-up, with minimal complications and good graft positioning. We recommend the arthroscopic procedure to surgeons who have good anatomic knowledge, advanced arthroscopic skills, and familiarity with the instrumentation.

Despite the success of open Latarjet procedure, the arthroscopic Latarjet holds many advantages, including:

1. Placement of the bone graft is more accurate under arthroscopic control. Several different views can be afforded by the arthroscopic technique that improve graft placement and reduce the chances of overhang and impingement.

2. Open surgery does not easily allow the treatment of concomitant pathologies such as SLAP tears and posterior labral lesions.
3. Concurrent anterior and posterior instability can be treated during the same arthroscopic surgical procedure using anterior and posterior bone blocks. This is not possible through a single open approach.
4. The risk of adhesions and shoulder stiffness is higher with an open technique than with arthroscopy.
5. If during an intended Bankart repair the tissue is determined to not be reconstructable, then an arthroscopic Latarjet offers an alternative to traditional open surgery without potentially having to reposition the patient.
6. As in other joints, arthroscopy offers the postoperative advantages of less pain, earlier mobility, quicker rehabilitation and faster return to sports.
7. An all-arthroscopic technique offers the patient an improved cosmetic result.
8. Arthroscopy reveals many previously unrecognized soft tissue and bony lesions underlying recurrent anterior shoulder instability.

How to manage the procedure

We recommend the use of the instrumentation for open Latarjet as it provides a reproducible and guided technique.

It is important to be familiar with the technique by starting with an open approach, but to begin doing this using the arthroscopic instrumentation set.

Once the surgeon is familiar with these instruments, he or she can begin the first stage of the surgery arthroscopically.

After this first stage is completed, the rest of the surgery should be performed by reverting to the open technique.

The surgeon should not move on to the next stage arthroscopically until he or she feels comfortable and is competent with the present stage.

This process should continue until the procedure is being performed all arthroscopically.

Knowledge of anatomy, education, 3D visualization, patience and work are the keys to perform this difficult but very effective shoulder surgery for the patient benefit.

DePuy Mitek and myself will do the best to support you to achieve this goal.

“Amities”,

Laurent LAFOSSE

1. Latarjet M. “Treatment of recurrent dislocation of the shoulder.”. *Lyon Chir* 1954;49:994-7.

2. Patte D, Bernageau J, Bancel P. *The anteroinferior vulnerable point of the glenoid rim*. New York: Marcel Dekker; 1985.


SUMMARY OF PROCEDURE

After evaluation, two holes are placed in the coracoid process, and reinforced with Top Hats. CHIA wire is passed through the two holes. The coracoid is then separated from the scapula using an Osteotome, leaving the conjoint tendon attached to the distal end. The coracoid graft is affixed to the Double Cannula using long screws. After splitting the subscapularis to expose the anterior glenoid, the coracoid graft is fixed to the glenoid with two bone screws. With the coracoid in this position, it fills the bone deficiency, and the conjoint tendon can provide a sling effect, stabilizing the shoulder.



THE DEPUY MITEK LATARJET INSTRUMENT PORTFOLIO

DePuy Mitek provides a specialized set of instruments designed specifically for the Latarjet procedure, whether performed arthroscopically or through the open technique. These tools offer distinct advantages and benefits to the surgeon.



Coracoid Drill Guide

The Coracoid Drill Guide allows for precise drill hole placement in the coracoid, ensuring that the two holes are exactly parallel. The guide is angled to allow an anatomical approach to the coracoid and accommodates two 1.5mm Coracoid K-wires.



Coracoid Holding Wire/Top Hat with Screw Implants

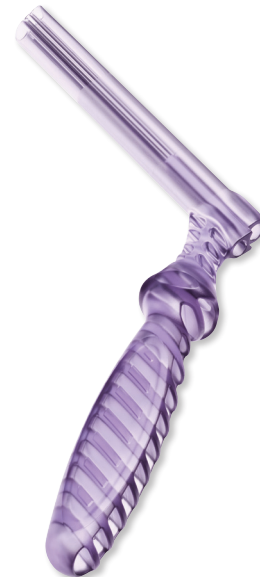The Coracoid Holding Wire maintains control of the coracoid after the osteotomy, and allows secure insertion of Top Hats.

The Top Hat prevents the bone from fracturing on reattachment. The Top Hat, in combination with the 3.5mm Cannulated Titanium Screws, allows for optimal compression fit.



Double Cannula/Single Cannula

The unique delivery Cannula is used for maneuvering the coracoid graft, granting control over the bone graft and enabling correct placement of the graft on the glenoid. Made of clear plastic for better visibility, the Cannula offers stability during K-wire insertion, drilling, and screw insertion.

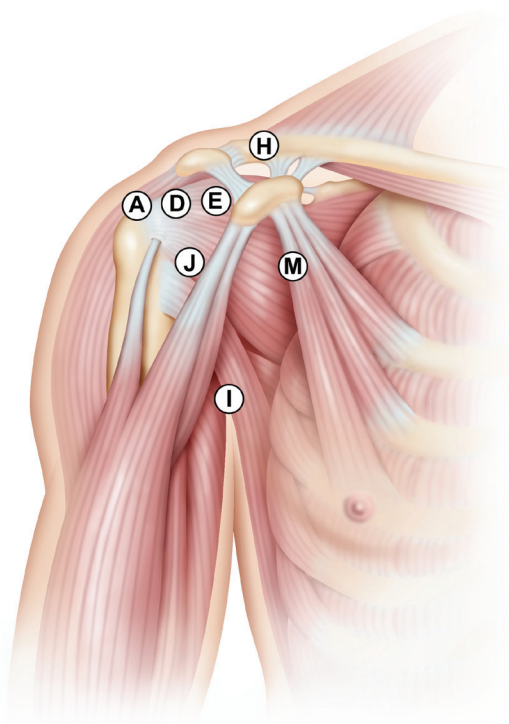


Curved Osteotome

Allows for more comfortable navigation around clavicle, enabling the correct angle and optimal size of coracoid bone when cut. The coracoid osteotomy is an exacting procedure for which the specially Curved Osteotome is an essential tool.



PORTALS



Portal A: Posterior Portal. Standard posterior portal in the soft spot of the shoulder. Used for visualization and for the switching stick to check if the coracoid graft is flush to the glenoid.

Portal D: Lateral Portal. Anterior to the long head of the biceps. Used for instruments (VAPR or shaver) during coracoid preparation and coracoid osteotomy. Used for visualization during the shoulder's anterior access, exposure, subscapularis split and fixation of graft.

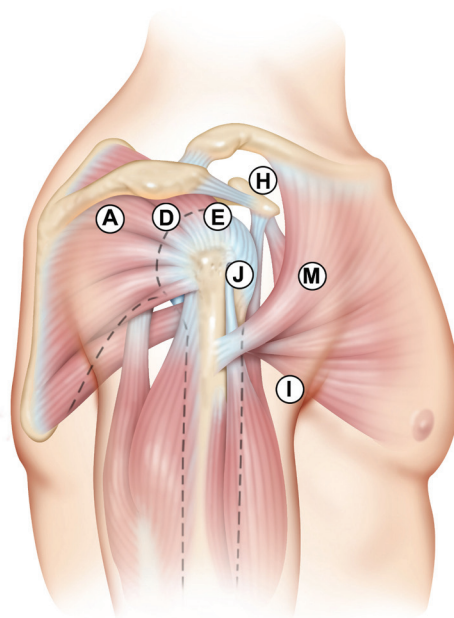
Portal E: Anterior Superior Portal. Placed in the rotator interval. Instruments like probe, VAPR or shaver are introduced here.

Portal H: Anterior Superior Portal – Above coracoid. Used to introduce the Coracoid Drill Guide, K-wires, Coracoid Step Drill, tap, wire retriever, CHIA and Osteotomes.

Portal I: Ancillary Portal. Used to make the subscap split with VAPR, shaver and subscap channeler. Also used for visualization during the preparation of the coracoid holes.

Portal J: Anterior Inferior Portal. Above Subscapularis. Alternate portal only used for visualization during the preparation, osteotomy, and transfer of the coracoid graft.

Portal M: Anterior Portal – Medial to the conjoint tendon. Used for the Double Barrel Cannula. Double Cannula always stays in this portal; during the osteotomy, coracoid fixation, subscap split and ultimate coracoid fixation to the glenoid.



LATARJET ARTHROSCOPIC SURGICAL TECHNIQUE

Steps

1. Joint evaluation and surgical final decision
2. Shoulder's elements access, exposure & preparation
3. Split of subscapularis
4. Preparation of coracoid holes
5. Coracoid osteotomy, mobilization & cannula fixation
6. Coracoid transfer through subscapularis
7. Coracoid-glenoid fixation

PATIENT POSITIONING: Prepare the patient in a standard manner for shoulder arthroscopy in a beach-chair position.

EVALUATION OF SHOULDER

JOINT EVALUATION AND SURGICAL FINAL DECISION

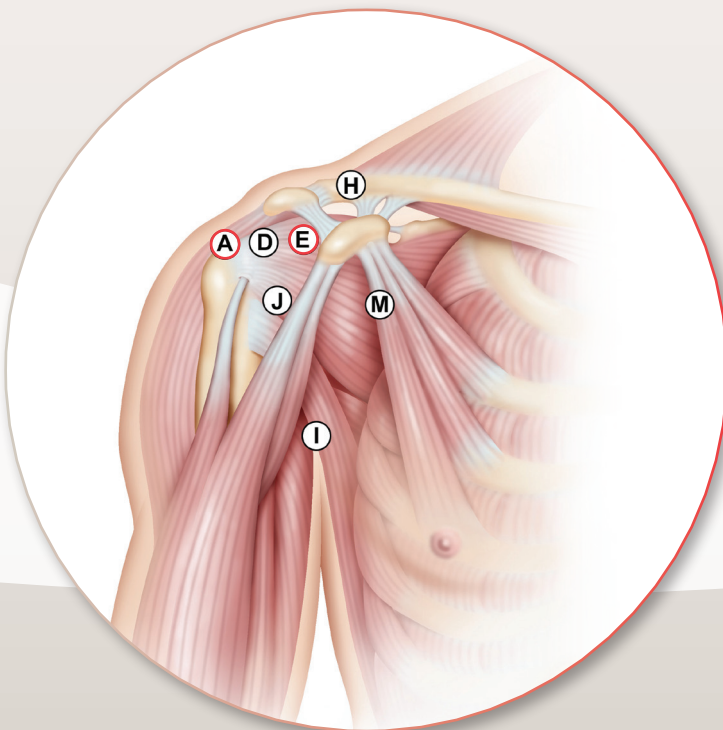
Portals

Portal A: Visualization

Portal E: Instruments

SINGLE PORTAL TECHNIQUE

- 1 a. Introduce the scope from portal A for air evaluation, with little air pressure, of dynamic instability before lavage.
- 1 b. Place the E portal for lavage. Probe to evaluate the Hill Sach's bone loss, the anterior capsule quality, humeral and labral attachment, eventual accessible bony Bankart.
- 1 c. Explore cuff and SLAP.
- 1 d. Release labrum from glenoid and explore eventual bony Bankart hidden by the spontaneous reattachment of capsule.
- 1 e. Confirm surgical decision and treat eventual associated lesions.

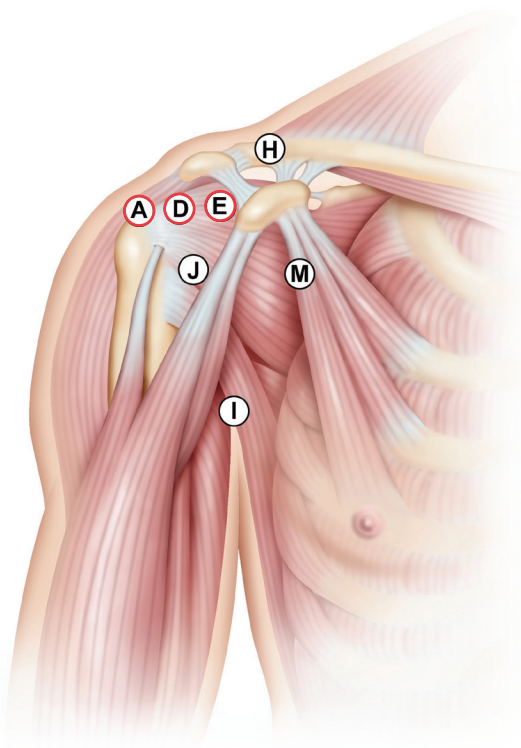


SHOULDER'S ELEMENTS ACCESS, EXPOSURE & PREPARATION

Portals

Portal A/D: Visualization

Portal E: Instruments



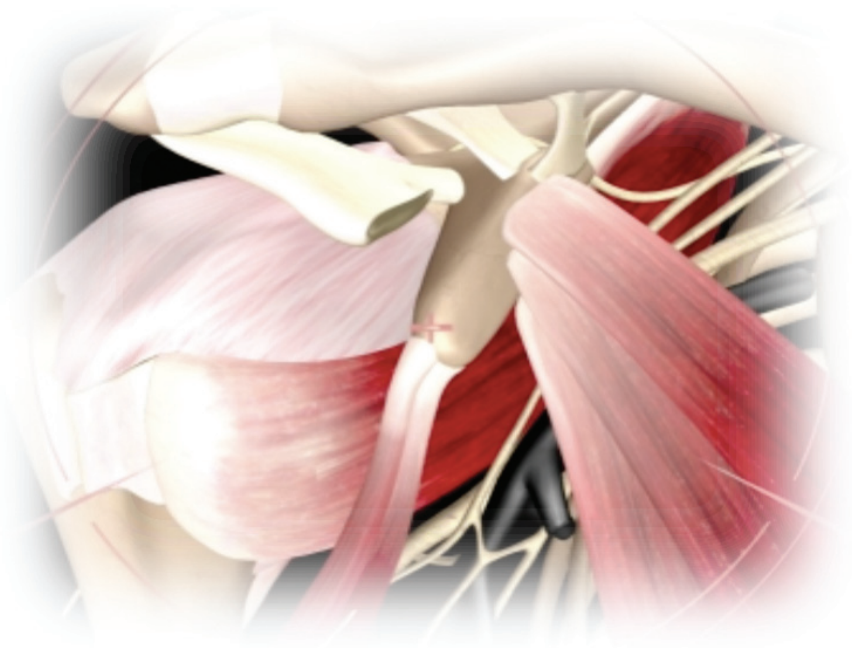
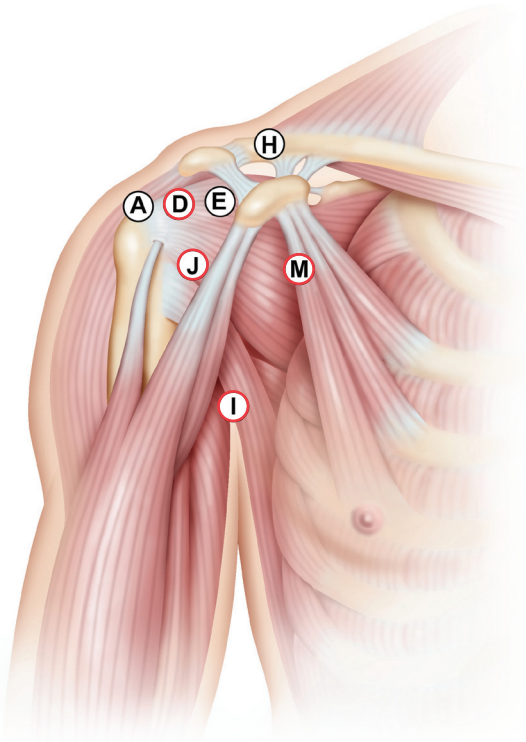
- 2 a. Determine where the bone graft will be placed by removing the labrum with the FMS shaver. Open the joint capsule with VAPR to fully expose the subscapularis muscle on the same level.
- 2 b. Open rotator interval by shaving the capsule between upper part of subscapularis tendon and SGHL (Superior Gleno-Humeral Ligament).
- 2 c. Determine the D portal by placing a Long Spinal Needle parallel to the upper part of the subscapularis tendon. As the coracoid is exposed usage of both VAPR and the FMS shaver will be necessary.
- 2 d. Expose the coracoid undersurface while allowing conjoint tendon (CT) to remain attached to coracoid by detaching the coracoacromial (CA) ligament. Release the lateral side of the conjoint tendon from the deltoid fascia as far as the pectoralis major insertion.
- 2 e. Move scope to the D portal. Visualizing from this portal, above the subscapularis tendon, allows viewing of both the articular and extra-articular sides of the subscapularis.
- 2 f. Remove remaining capsule tissue from the location where the bone graft will be placed, and from the visualization path.
- 2 g. Remove bony Bankart and abrade anterior glenoid neck.
- 2 h. Remove the end of the bursa under the coracoid. This is the last step in the exposure of the coracoid process before moving on to the splitting of the subscapularis.
- 2 i. Determine the I, M & J portal locations by placing the three needles under visualization from the D portal.

Portals

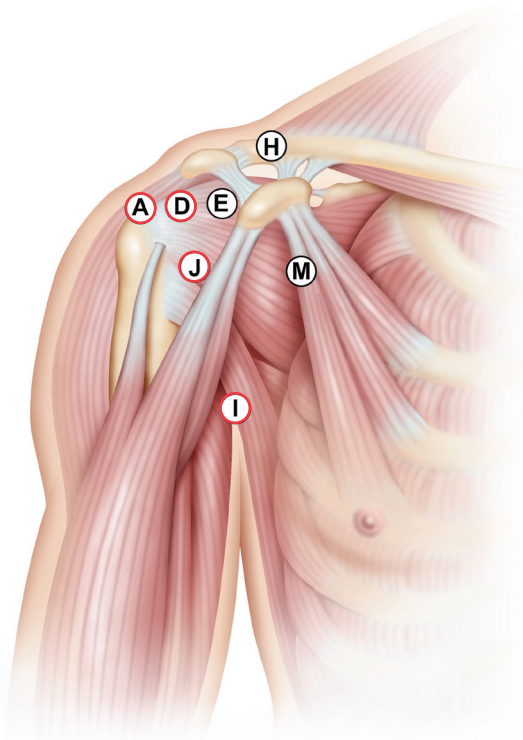
Portal J: Visualization

Portal D, I & M: Instruments

- 2 j. Place the Subscapularis Channeler in the M portal. Place VAPR in the I portal. Place the scope in the J portal. Use the Switching Stick on D portal to elevate the deltoid and expose the coracoid process.
- 2 h. Detach the pectoralis minor (PM), exposing both upper and inferior sides of the muscle. Splitting the pectoralis minor from the conjoint tendon (CT) requires use of a variable landmark, and caution must be used to avoid the musculo-cutaneous nerve in this location behind the pectoralis minor. The VAPR should be kept close to the coracoid, always facing the bone. All bursa and fat should be removed to fully expose the coracoid junction between the vertical and horizontal parts of the bone.



SUBSCAPULARIS SPLIT



Portals

Portal D & J: Visualization


Portal A I & J: Instruments

Instruments

Subscapularis Channeler

Switching Stick

To create the split in the subscapularis, fully visualize both sides of the muscle. The location of the split will be at the union between 2/3 superior and 1/3 inferior of the muscle, at the same level as the future location of the graft. The joint should already be prepared as per steps 2d to 2h. Use this level as a landmark to introduce a Switching Stick inside out. Be aware that the plexus will obstruct the orientation of the Switching Stick laterally to the conjoint tendon once the stick is passed through the subscapularis muscle. An assistant should handle the scope on D portal above the subscapularis tendon, while the surgeon uses both hands to operate the Switching Stick and the Subscapularis Channeler.



- 3 a.** Insert a Switching Stick from posterior A portal, through the split of the subscapularis with one hand. With the other hand, use the Channeler to maintain the muscle, recline the plexus and insure the CT is medial.
- 3 b.** Once the SS is out of the CT, place the scope back to the J portal and use the VAPR from the I portal to perform the split until the glenoid is exposed. Use caution to avoid any damage to the humeral cartilage.
- 3 c.** Enlarge the split and confirm adequate access to the glenoid using the Subscapularis Channeler.

PREPARATION OF CORACOID HOLES

Portals

Portal J: Visualization

Portal D & H: Instruments (J) (D) (H)

Instruments

Coracoid Drill Guide

Coracoid K-wires

Coracoid Step Drill

Coracoid Step Tap

Portals

Portal J: Visualization

Portal D, E & H: Instruments (J) (D) (E) (H)

Instruments

Coracoid Holding Wire

Wire Retriever

Portals

Portal D: Visualization

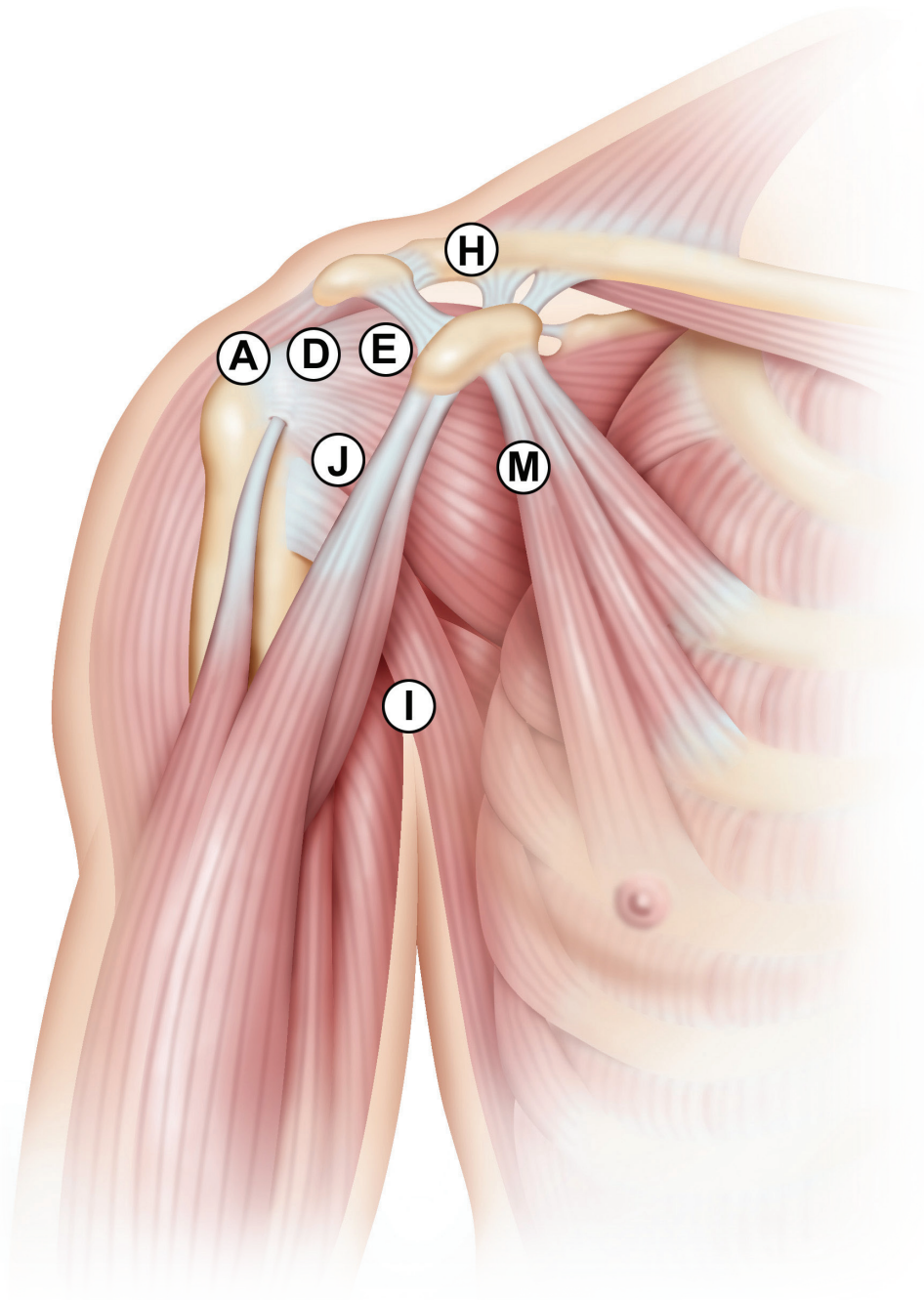
Portal J: Visualization

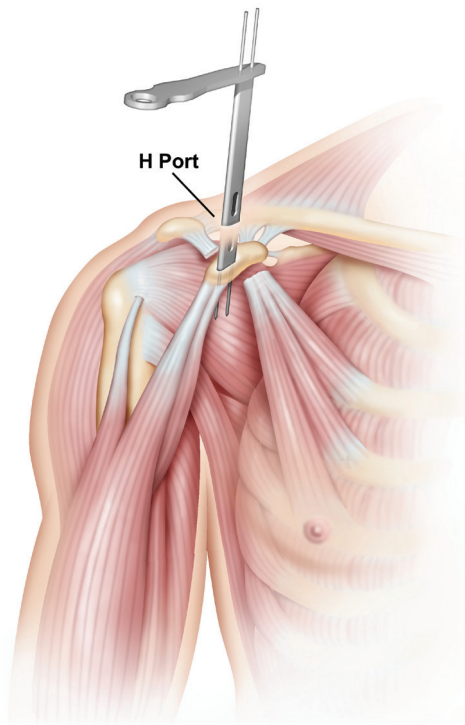
Portal H: Instrument (J) (D) (H)

Instruments

Top Hats

Top Hat Screw Driver





4 a. Place visualization device in the J portal, positioned on the axis of the coracoid process, and rotate the scope for a lateral viewpoint. Introduce the Switching Stick through the D portal and lift the deltoid above the coracoid process. Landmark the coracoid's tip at the conjoint tendon insertion 90° to the coracoid axis, using a long spine needle medial and inferior to the D portal.

4 b. Determine the H portal's location by using a second needle above the middle of the coracoid, as medially as possible. The head of the patient may be in the way during the drilling stage. Place the H portal in a location that accommodates the space required by the drill.

4 c. Make a minimal incision to introduce the Coracoid Drill Guide through the H portal. Place the Coracoid Drill Guide flush on top of the coracoid, so that the oblique axis is relative to the long spine needle marking the coracoid's end. The guide is parallel to the coracoid between the medial 1/3 and the lateral 2/3 of the bone.

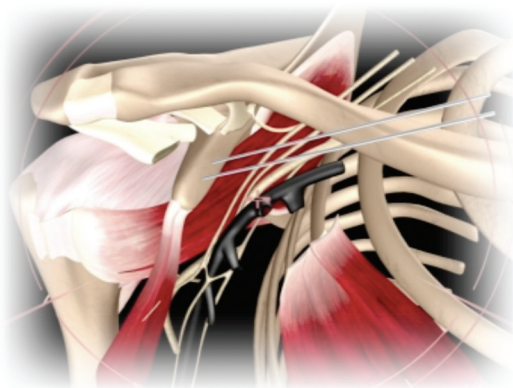
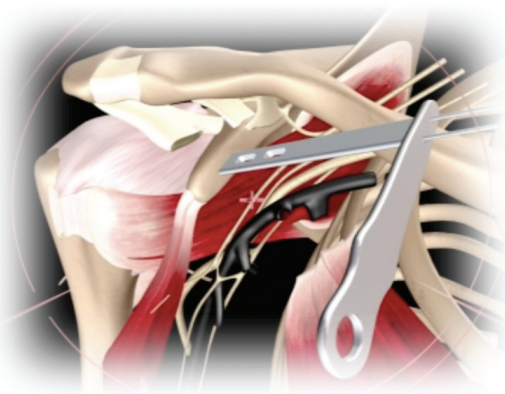4 d. Introduce K-wires in alpha and beta holes. The alpha hole should be 1cm away from the distal tip of the coracoid process. The end of the K-wire should visibly protrude.

4 e. Locate the final position of the beta hole relative to the alpha axis and drill the Coracoid K-wire through the Coracoid Drill Guide in the beta position.

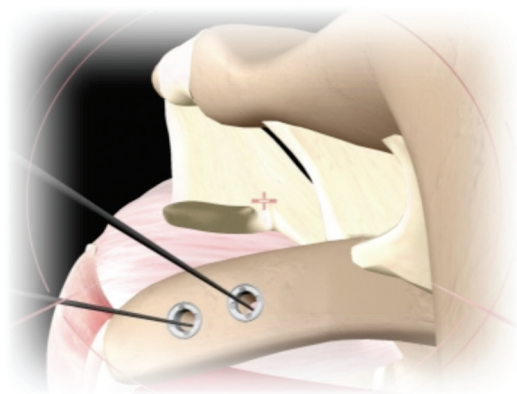
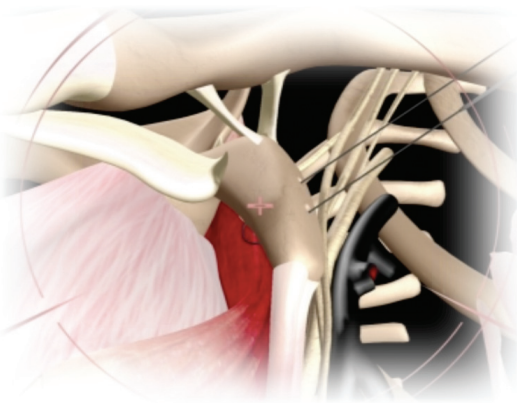
4 f. Check the position of both K-wires. If they are not located correctly, replace them.

4 g. Remove the Coracoid Drill Guide, leaving the Coracoid K-wires in the alpha and beta holes.

4 h. Drill the alpha hole completely through the coracoid, over the Coracoid K-wire, using the Coracoid Step Drill.



- 4 i. Remove the Coracoid Step Drill from the alpha hole and remove the K-wire.
- 4 j. Drill the beta hole completely through the coracoid, over the Coracoid K-wire in the same manner.
- 4 k. Introduce the Coracoid Holding Wire (CHIA) through the Coracoid Step Tap. Thread the Coracoid Step Tap through the alpha hole first, and then the beta hole. Leave the step tap in the beta hole.
- 4 l. Push the Coracoid Holding Wire (CHIA) through the Coracoid Step Tap into the beta hole. Ensure that the kite loop is threaded first, and totally protrudes through the coracoid.
- 4 m. Pass a Suture Manipulator Grasper through the E portal and grasp the Coracoid Holding Wire (CHIA). Remove the Coracoid Step Tap, leaving the Coracoid Holding Wire (CHIA) inside the beta hole.
- 4 n. Use the Suture Manipulator Grasper to lead the Coracoid Holding Wire (CHIA) toward the alpha hole. Retrieve the kite loop and pull it out using the Wire Retriever.
- 4 o. Cut the loop of the CHIA and place a clamp on the end of the wire exiting from the beta hole. Put Top Hats in the alpha and beta holes.
- 4 p. Put the alpha end of the Coracoid Holding Wire in the Top Hat from portal H.
- 4 q. Screw in the Top Hat using the Top Hat Screw Driver.
- 4 r. Switch the clamp to the alpha end of the wire. Put the beta end of the wire in the Top Hat from portal H. Screw in the Top Hat using the Top Hat Screw Driver.



CORACOID OSTEOTOMY, MOBILIZATION & CANNULA FIXATION

THREADING CORACOID HOLDING WIRES THROUGH THE DOUBLE CANNULA

Portals

Portal J: Visualization

Portal M: Instrument Double Cannula

Portal I, D & H: Burr

Portal H: Osteotomes

Instruments

Cannula Obturators and Double Cannula

Crochet Hooks

Portals

Portal J: Visualization

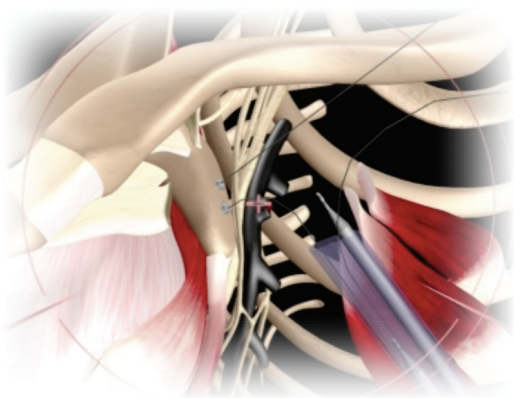
Portal D: Burr

Portal H: Osteotomes

Instruments

Curved Osteotome

Straight Osteotome



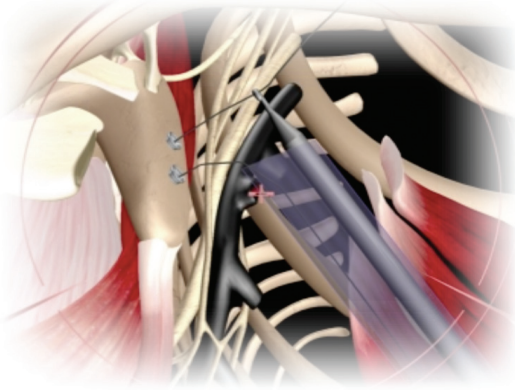
5 a. Insert the two Cannula Obturators into the Double Cannula Positioning sleeves.

5 b. Enlarge M portal using a large trocar. Bring the distal end of the Double Cannula Positioning sleeves close to the alpha and beta holes.

5 c. Remove the two Cannula Obturators and insert two Crochet Hooks into the Double Cannula.

5 d. Grab the Coracoid Holding Wire from the alpha hole with the first Crochet Hook and pull the wire, holding it tightly against the Double Cannula. Put the Obturator back into the Cannula around the Coracoid Holding Wire inside the slot.

5 e. Grab the second Coracoid Holding Wire from the beta hole with the second Crochet Hook, and pull the wire tightly to attach it to the Positioning Double Cannula edge.



5 f. Pull both Crochet Hooks through the Positioning Double Cannula sleeves.

5 g. Abrade the surface underneath the coracoid, creating a groove in order to lead the intended split. Ensure a safe margin between the groove and beta hole, leaving enough bone matter around the beta hole in order to not compromise it.

It is important to manage a 360° decortication of the coracoid at the site of the osteotomy. The burr should be placed in the I, D, and H portals to achieve this goal.

5 h. Cut the coracoid using the Straight and Curved Osteotomes.

5 i. Pull both Coracoid Holding Wires (CHIA) to hold the coracoid process against the Double Cannula.

5 j. Remove the Cannula Obturator from the Positioning Double Cannula and insert the two Coracoid 3.5mm Screws.

5 k. Thread the Cannulated Coracoid 3.5mm Screws into the two Top Hats in the alpha and beta holes. Continue until the screw edge is seen through the other end of the Cannula.

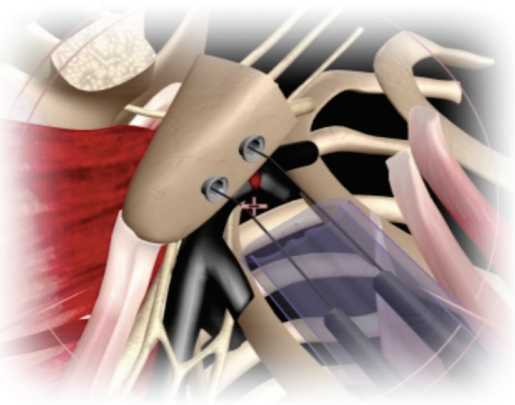5 l. Clamp the looped end of the Coracoid Holding Wire (CHIA) and pull the Coracoid Holding Wire through the Cannula until it is tight, holding the coracoid process against the Cannula.

5 m. Tighten the Coracoid 3.5mm Screws until they completely penetrate through the alpha and beta holes of the coracoid.

5 n. Final tightening of the coracoid process to the Cannula must be done with Cannulated 4mm Screw Driver. Check to ensure solid fixation.

5 o. Remove the CHIA Wire and put the two Cannula Plugs on the long screws in order to decrease fluid leakage.

5 p. Use a burr to smooth the coracoid surface. Have the assistant hold the visualization in the J portal, while the surgeon holds the burr in the D portal and the Double Cannula in the M portal.



CORACOID TRANSFER THROUGH THE SUBSCAPULARIS

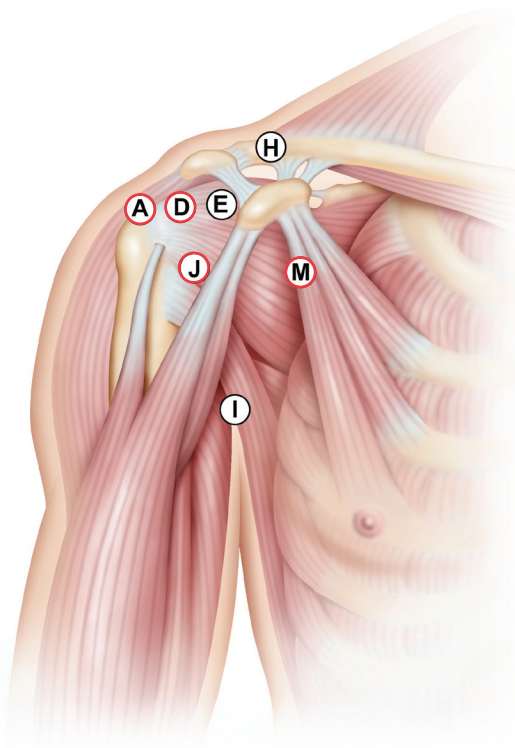
POSITIONING OF THE SHOULDER AND POSITIONING OF THE DOUBLE CANNULA

Portals

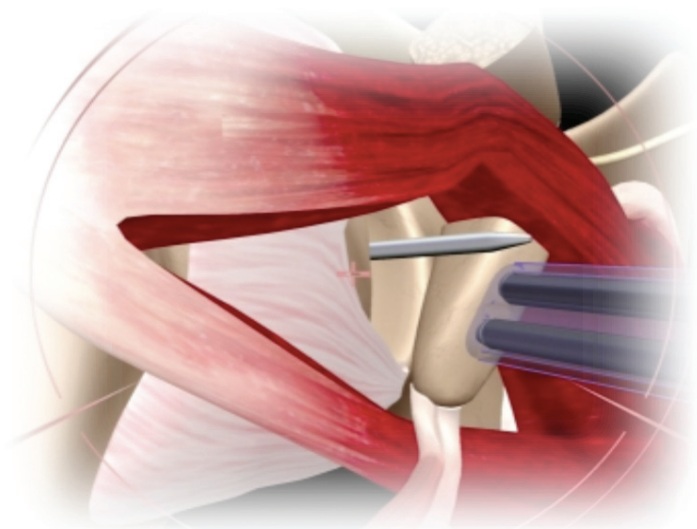
Portal J & D : Visualization

Portal M: Instruments

Portal A: Switching Stick

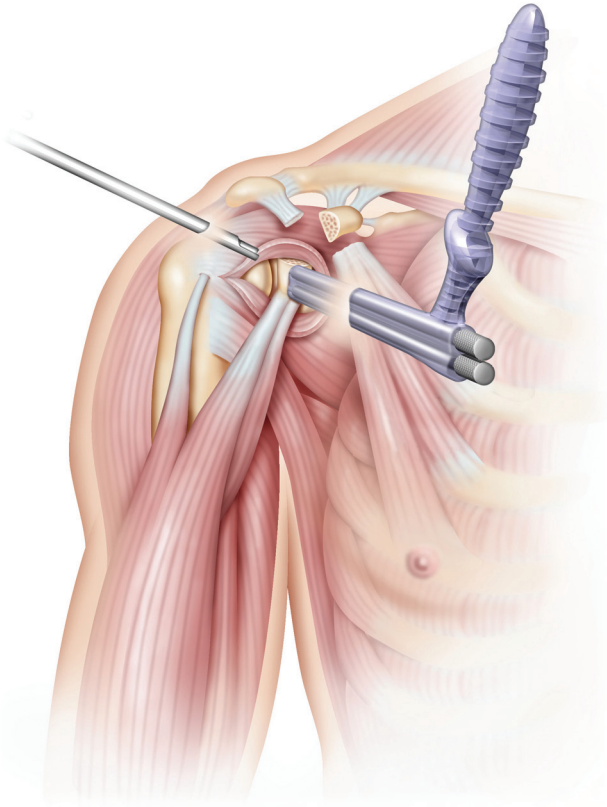


- 6 a. Place the switching stick in the A portal, using the D portal for visualization. Use caution to avoid disturbing the axillary nerve. Shaving of the muscle and joint capsule may be needed at this stage. Fully expose the glenoid neck. Mobilize the coracoid process and make sure the conjoint tendon is fully released from the pectoralis minor.
- 6 b. Place the scope back in the J portal. Transfer the coracoid process through the split in the subscapularis, aided by the Switching Stick. Place the coracoid process in its desired position on the anterior rim of the glenoid. Use the Switching Stick to help control the coracoid, ensuring it is accurately aligned with the glenoid surface.



- 6 c. Decrease the glenoid anteversion by having an assistant pull the scapula backward in order to place the shoulder in proper position for the alignment of the Double Cannula.
- 6 d. Push the Double Cannula medially as parallel to glenoid surface as possible, in order to achieve an optimal angle for fixation screws.

CORACOID-GLENOID FIXATION



Portals

Portal J: Visualization

Portal M: Instruments

Portal D: Visualization

Portal M: Double Cannula

Instruments

Bristow-Latarjet Cortical Screws

2.5mm Cannulated Screw Driver

2.5mm Solid Screw Driver

Glenoid K-wires

Glenoid 3.2mm Drill

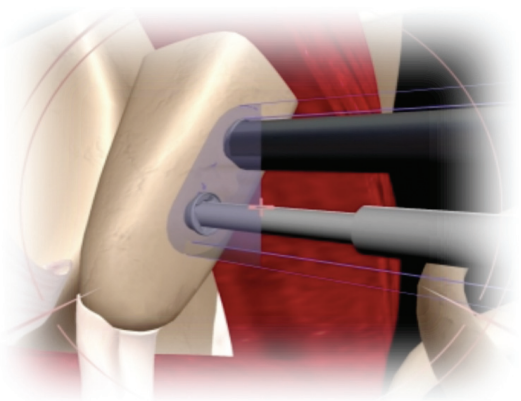
- 7 a. Start from the alpha hole. Insert a Glenoid K-wire through the Coracoid 3.5mm Screw located in the alpha hole and drill across the glenoid.

The Glenoid K-wire should exit the skin. Strongly clamp the K-wire on the posterior side of the shoulder. At this stage it is essential to be at a maximum 20-degree angle differential vs. the glenoid plane. The exit location of the Glenoid K-wire should not be further than 5cm from the A portal.

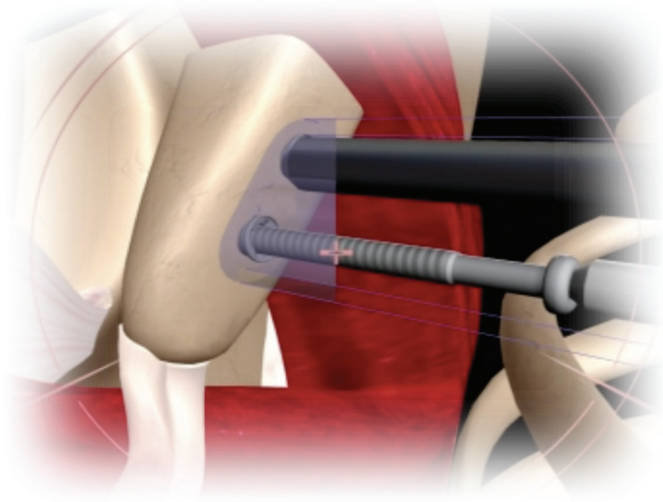
- 7 b. Drill the beta Glenoid K-wire in the same fashion, ensuring that the two K-wires are parallel.

- 7 c. Remove the Coracoid 3.5mm Screw from the alpha hole.

- 7 d. Drill the glenoid alpha hole using the Glenoid 3.2mm Drill. This should be done over the K-wire and through the Coracoid Positioning Cannula. Once the drill has gone through the glenoid, use the scale that is marked on the Glenoid 3.2mm Drill to determine the length of the required screw.

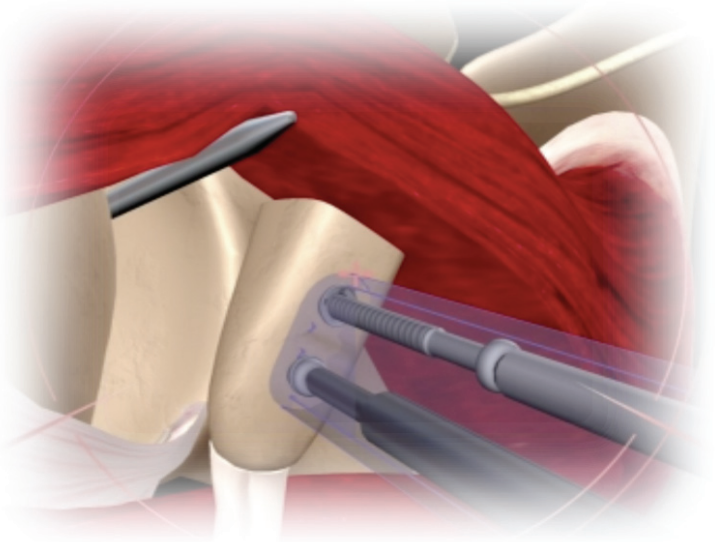


- 7 e. Load the Latarjet Cortical Screw over the Glenoid K-wire and insert into the alpha hole.



- 7 f. Thread the screw into the glenoid using the 2.5mm Cannulated Screw Driver. Do not over-tighten the screw.

- 7 g. Repeat steps 7 a. to 7 f. for the beta hole.



- 7 h. Confirm that the coracoid graft is correctly placed.

- 7 i. Remove both Glenoid K-wires by pulling them out from the posterior portal. Tighten both screws using the Solid Screw Driver (red handle).

- 7 j. Remove the Double Cannula from M portal.

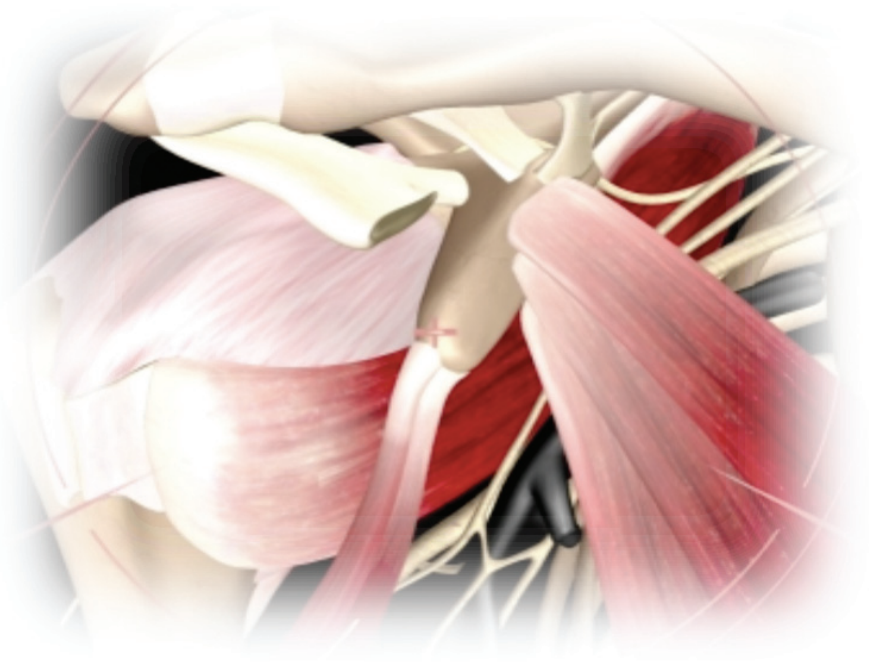
LATARJET OPEN SURGICAL TECHNIQUE

STEPS

1. Exposure
2. Preparation of coracoid holes
3. Cutting the coracoid
4. Fixing the Double Cannula to the coracoid, and exposure of both sides of the subscapularis
5. Coracoid transfer through the subscapularis
6. Coracoid-glenoid fixation

EXPOSURE

- 1 a. Use a standard delto-pectoral approach.
- 1 b. The cephalic vein is protected and retracted laterally with the deltoid muscle. The coracoid is exposed from its tip to the insertion of the coracoclavicular ligaments at the base.
- 1 c. The coracoacromial ligament is dissected from the lateral aspect of the coracoid, as is the pectoralis minor tendon from the medial side of the coracoid. This medial surface of the coracoid will later be prepared for contact against the anterior joint evaluation.



PREPARATION OF CORACOID HOLES

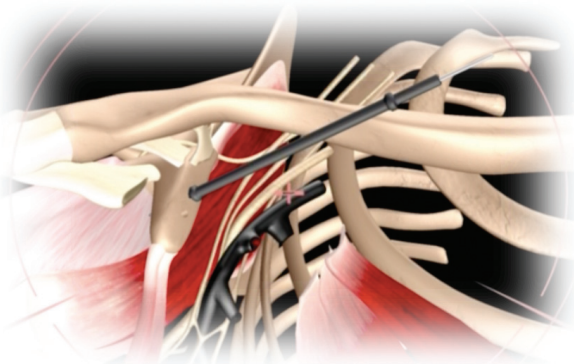
Instruments

Coracoid K-wires

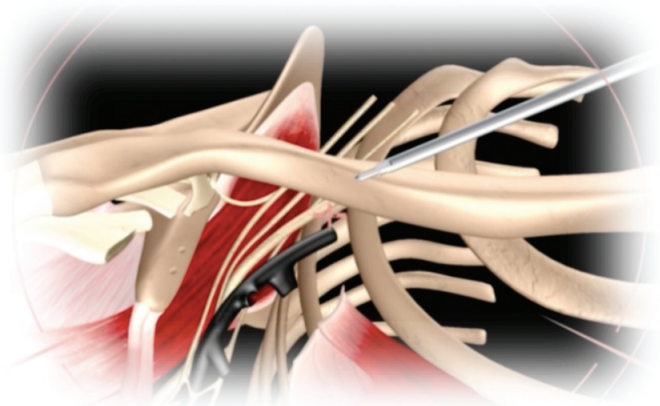
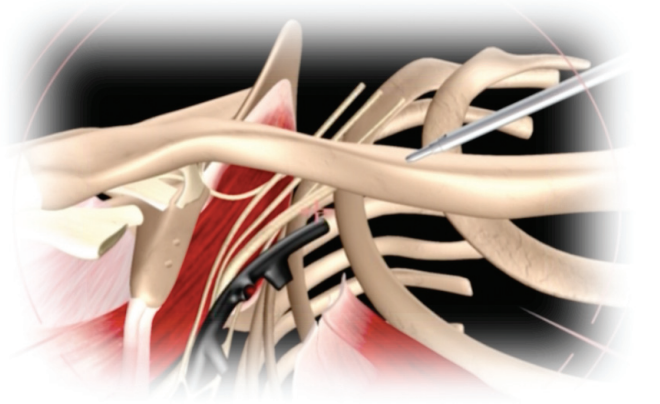
Coracoid Step Drill

Coracoid Step Tap

- 2 a. Landmark the coracoid's tip at the CT insertion, 90° to the coracoid axis using a Long Spine Needle.
- 2 b. Introduce the Coracoid Drill Guide. Place the Coracoid Drill Guide flat on top of the coracoid, so that the oblique axis is relative to the Long Spine Needle marking the coracoid's end. The guide should be parallel to the coracoid between the medial third and the lateral two thirds of the bone.
- 2 c. Introduce the Coracoid K-wires in alpha and beta holes. The alpha hole should be 1cm away from the distal tip of the coracoid process. The end of the K-wire should visibly protrude from the other side of the bone.
- 2 d. Locate the final position of the beta hole relative to the alpha axis and drill the Coracoid K-wire through the Coracoid Drill Guide in the beta position.
- 2 e. Check the position of both K-wires. If they are not located correctly, replace them.
- 2 f. Remove the Coracoid Drill Guide, leaving the Coracoid K-wires in the alpha and beta holes.
- 2 g. Drill the alpha hole completely through the coracoid, over the Coracoid K-wire, using the Coracoid Step Drill.
- 2 h. Remove the Coracoid Step Drill and Coracoid K-wire from alpha and remove the K-wire.
- 2 i. Drill the beta hole completely through the coracoid, over the Coracoid K-wire, in the same manner.



- 2 j. Thread the Coracoid Step Tap through the alpha hole first, and then through the beta hole.



- 2 k. Put Top Hats in alpha and beta holes.

- 2 l. Screw in the Top Hats using the Top Hat Screw Driver.

CUTTING THE CORACOID

Instruments

Curved Osteotome

Straight Osteotome

- 3 a. Cut the coracoid using the Straight and Curved Osteotomes. Ensure a safety margin between the osteotomy and the beta hole, leaving enough bone matter around the beta hole in order to not compromise it.

FIXING THE DOUBLE CANNULA TO THE CORACOID

Instruments

Top Hats

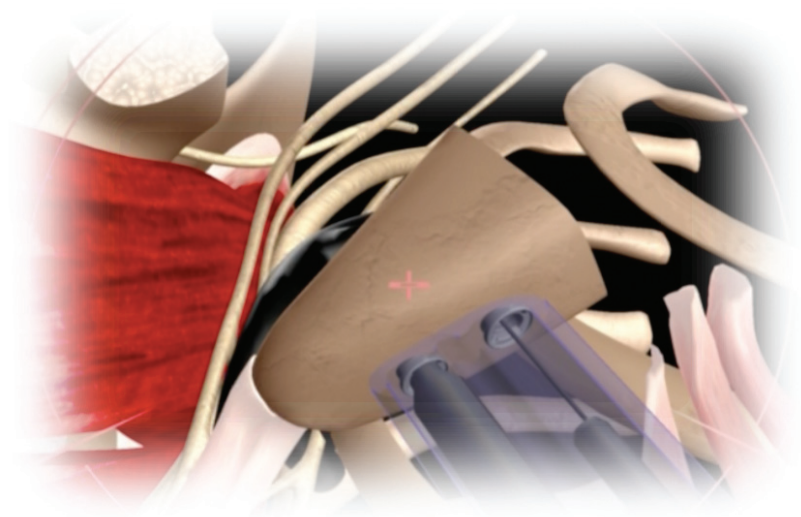
Top Hat Screw Driver

Double Cannula

Coracoid 3.5mm Screws

4.0mm Screw Driver

- 4 a. Insert the two Coracoid 3.5mm Screws in the two sleeves of the Double Cannula.
- 4 b. Thread the cannulated Coracoid 3.5mm Screws into the two Top Hats in the alpha and beta holes. Continue until the screw edge is seen through the other end of the Cannula.
- 4 c. Tighten the Coracoid 3.5mm Screws until they completely penetrate through the alpha and beta holes of the coracoid.
- 4 d. Final tightening of the coracoid process to the Cannula must be done with Cannulated 4mm Screw Driver. Check to ensure solid fixation.



CORACOID TRANSFER THROUGH THE SUBSCAPULARIS

POSITIONING OF THE SHOULDER AND POSITIONING OF THE DOUBLE CANNULA


5 a. Fully expose the glenoid neck. Mobilize the coracoid process and make sure the conjoint tendon is fully released from the pectoralis minor.

5 b. Transfer the coracoid process through the split of the subscapularis.

Place the coracoid process in its desired position on the anterior rim of the glenoid. The coracoid should be flat on the glenoid surface.

5 c. The assistant should pull the scapula backward in order to decrease the glenoid anteversion.

5 d. Push the Double Cannula medially as parallel to glenoid surface as possible, in order to achieve an optimal angle for fixation screws.



CORACOID-GLENOID FIXATION

Instruments

Glenoid K-wires

Glenoid 3.2mm Drill

Bristow-Latarjet Cortical Screws

2.5mm Cannulated Screw Driver

2.5mm Solid Screw Driver

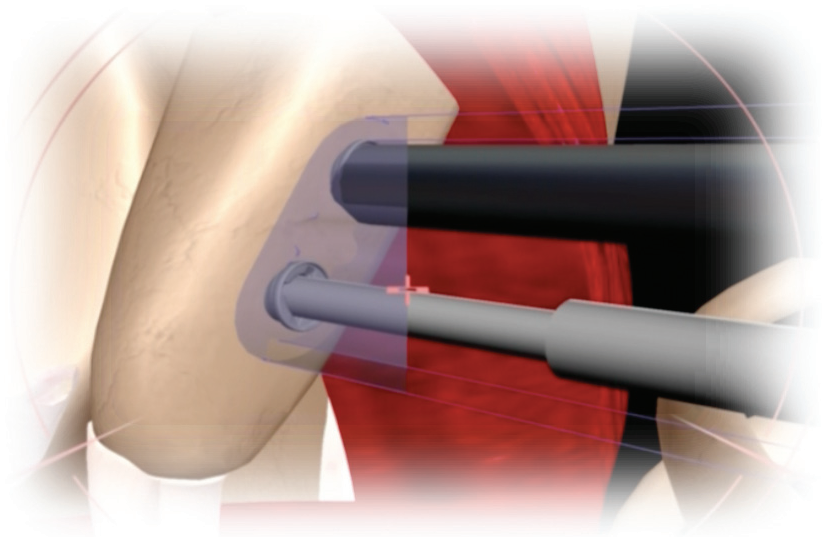
- 6 a. Start from the alpha hole: Insert a Glenoid K-wire through the Coracoid 3.5mm Screw located in the alpha hole and drill across the glenoid.

The Glenoid K-wire should exit the skin. Strongly clamp the K-wire on the posterior side of the shoulder. At this stage it is essential to be at a maximum 20-degree angle differential vs. the glenoid plane.

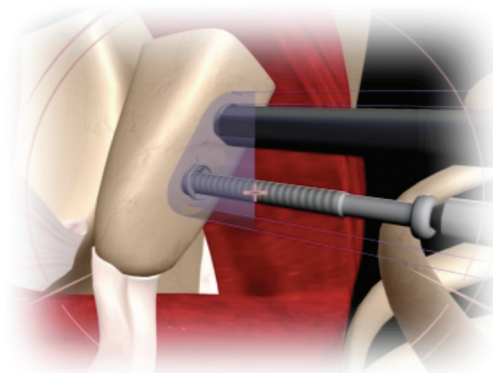
- 6 b. Drill the beta Glenoid K-wire in the same fashion, ensuring that the two K-wires are parallel.

- 6 c. Remove the Coracoid 3.5mm Screw from the alpha hole.

- 6 d. Drill the glenoid alpha hole using the Glenoid 3.2mm Drill. This should be done over the K-wire and through the Coracoid Positioning Cannula. Once the drill has gone through the glenoid, use the scale that is marked on the Glenoid 3.2mm Drill to determine the length of the required screw.

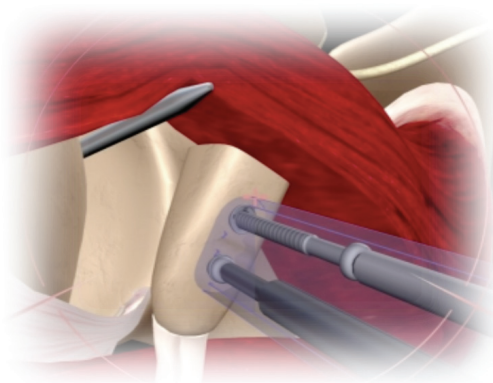


- 6 e. Load the Latarjet Cortical Screw over the Glenoid K-wire and insert into the alpha hole.



6 f. Thread the screw into the glenoid using the 2.5mm Cannulated Screw Driver. Do not over-tighten the screw.

6 g. Repeat steps 6 a. to 6 f. for the beta hole.



6 h. Remove both Glenoid K-wires by pulling them from the posterior part of the shoulder.



6 i. Tighten both bone screws using the Solid Screw Driver (red handle).

6 j. Remove the Double Cannula.



TRANSITIONING FROM OPEN TO ARTHROSCOPIC

PROCEDURAL STEP	SURGERY 1 Date: Time:	SURGERY 2 Date: Time:	SURGERY 3 Date: Time:	SURGERY 4 Date: Time:
1. Joint evaluation and final decision for surgery	Time: _____ __Arthro __OPEN	Time: _____ __Arthro __OPEN	Time: _____ __Arthro __OPEN	Time: _____ __Arthro __OPEN
2. Shoulder access, exposure, and preparation	Time: _____ __Arthro __OPEN	Time: _____ __Arthro __OPEN	Time: _____ __Arthro __OPEN	Time: _____ __Arthro __OPEN
3. Split of subscapularis	Time: _____ __Arthro __OPEN	Time: _____ __Arthro __OPEN	Time: _____ __Arthro __OPEN	Time: _____ __Arthro __OPEN
4. Preparation of coracoid holes	Time: _____ __Arthro __OPEN	Time: _____ __Arthro __OPEN	Time: _____ __Arthro __OPEN	Time: _____ __Arthro __OPEN
5. Coracoid osteotomy, mobilization, & cannula fixation	Time: _____ __Arthro __OPEN	Time: _____ __Arthro __OPEN	Time: _____ __Arthro __OPEN	Time: _____ __Arthro __OPEN
6. Coracoid transfer through subscapularis	Time: _____ __Arthro __OPEN	Time: _____ __Arthro __OPEN	Time: _____ __Arthro __OPEN	Time: _____ __Arthro __OPEN
7. Coracoid glenoid fixation	Time: _____ __Arthro __OPEN	Time: _____ __Arthro __OPEN	Time: _____ __Arthro __OPEN	Time: _____ __Arthro __OPEN



DePuy Mitek, Inc.
325 Paramount Drive
Raynham, MA 02767
USA
Tel: +1 (800) 382-4682

www.depuy.com

©DePuy Mitek, Inc. 2011.
All rights reserved.

P/N 901134 4/11 AADB/LP

**DePuy Mitek EMEA, a division of
Johnson & Johnson Medical Spa**
Via del Mare, 56
00040 Practica di Mare, Rome, Italy
Tel: +39 906 9119 41
Fax: +39 906 9119 4090



Mixed Sources
Product group from well-managed
forests, controlled sources and
recycled wood or fiber
www.fsc.org Cert no. SW-COC-002514
© 1996 Forest Stewardship Council



never stop moving®

DePuy
companies of *Johnson & Johnson*